

RESEARCH PAPER

The effect of berberine nanomicelles on hepatic cirrhosis in bile duct-ligated rats

Seyed Pouyan Pishva¹, Seyyedeh Elaheh Mousavi², Zahra Mousavi¹, Mahmoud Reza Jaafari^{3,4}, Ahmad Reza Dehpour², Seyed Mahdi Rezayat Sorkhabadi^{1,2*}

¹Department of Pharmacology & Toxicology, Faculty of Pharmacy, Pharmaceutical Sciences Branch, Islamic Azad University, Tehran, Iran (IAUPS)

²Department of Pharmacology, School of Medicine, Tehran University of Medical Sciences, Tehran, Iran

³Nanotechnology Research Center, Pharmaceutical Technology Institute, Mashhad University of Medical Sciences, Mashhad, Iran

⁴Department of Pharmaceutical Nanotechnology, School of Pharmacy, Mashhad University of Medical Sciences, Mashhad 91775-1365, Iran

ABSTRACT

Objective (s): The anti-fibrotic effect of chronic berberine (BBR) had demonstrated previously in a rat model of bile duct ligation (BDL). The aim of present study was to investigate hepatoprotective effect of BBR nanomicelles on liver cirrhosis induced by BDL in male rats.

Materials and Methods: After 21 days of drugs' treatments, the serum and tissue levels of hepatic markers were measured and pathologic evaluations performed.

Results: BDL could markedly increase aspartate aminotransferase (AST), alanine aminotransferase (ALT), LDH, and total bilirubin (TBIL) serum levels and tissue tumor necrosis factor-alpha (TNF- α) level along with reductions in tissue levels of key antioxidants glutathione (GSH) and superoxide dismutase (SOD) as well as total protein. On the other hand, silymarin (100 mg/kg, p.o.), BBR (100 mg/kg) and BBR nanomicelles (50 mg/kg, p.o.) markedly decreased AST and ALT while enhanced GSH. In addition, BBR nanomicelles (50 mg/kg, p.o.), silymarin (100 mg/kg, p.o.) and BBR (100 mg/kg, p.o.) groups showed a considerable increase in SOD. BBR nanomicelles (50 mg/kg, po.) significantly lowered TNF- α . In addition, nanoBBR treatment prevented liver cirrhosis in histopathologic analysis.

Conclusion: Formulation of BBR may represent a worthy approach to enhance the effect of it in liver injuries.

Keywords: Berberin, Bile duct ligation, Hepatoprotection, Nanoberberin, Oxidative stress

How to cite this article

Pishva SP, Mousavi SE, Mousavi Z, Jaafari MR, Dehpour AR, Rezayat Sorkhabadi SM. The effect of berberine nanomicelles on hepatic cirrhosis in bile duct-ligated rats. *Nanomed J*. 2018; 5(4): 199-209. DOI: 10.22038/nmj.2018.05.00003

INTRODUCTION

Bile duct ligation (BDL) induces a type of liver fibrosis, which resembles to biliary fibrosis in humans both etiologically and pathogenetically [1, 2]. BDL leads to an acute obstructive jaundice in two weeks, which progress to cirrhosis in 4 or 6 weeks [3, 4]. Liu et al. made evident that excessive production of superoxide and hydroxyl radicals occurs in the blood and the liver with obstructive jaundice-induced by common BDL in rats [5]. BDL stimulates the proliferation of

hepatocyte progenitors (biliary epithelial and oval cells), resulting in bile ductules proliferation along with portal inflammation and fibrosis [6]. Accumulation of inflammatory cells and bile acids in the liver tissue may result increased free radicals in biliary obstruction [7, 8]. Bile acids particularly boost reactive oxygen species (ROS) released by polymorphonuclear leukocytes [9]. Lipid peroxides levels in hepatic tissue also increased in BDL rats [10]. Free radicals might participate in the development of hepatic fibrosis in biliary obstruction [11, 12]. Cholestasis by itself lowers antioxidative capacities in the liver mitochondria of BDL rats [13].

* Corresponding Author Email: rezayat@tums.ac.ir

Note. This manuscript was submitted on July 25, 2018; approved on December 30, 2018

Berberine (BBR), called Umbellatine as well, is an alkaloid extracted originally from the commonly-used Chinese herb Huanglian (*Rhizoma Coptidis*); and this constituent is also existed in Huangbai (*Cortex Phellodendri Amurensis*) [14]. BBR possess various functions, for example antimicrobial, immunomodulatory, anti-carcinoma, antihyperlipidemic and mitigating neural disorder's functions [15, 16], anti-inflammation, reducing blood sugar, lowering blood pressure, antagonizing arrhythmia, protecting the liver, etc [17].

It was shown that improvement of experimental hepatic fibrosis by BBR contributes to its antioxidative activity [18]. Additionally, BBR pretreatment protected against hepatic ischemia/reperfusion in rats. BBR attenuated the histopathologic damage, restored the liver function, and decreased the oxidative stress level [19]. Several studies showed BBR inhibitory effects on chemically-induced cytotoxicity, lipid peroxidation, and oxidative stress in the liver [20, 21].

Following the oral BBR administration (200 mg/kg), it distributed predominantly in the liver [23, 24]. In rats, BBR mainly excreted by the hepatobiliary system and kidneys in the form of metabolites [23], however; BBR has poor oral bioavailability and high toxicity [25]. Lately, nanotechnology has attracted more attention because of the targeted delivery of therapeutic agents into the liver [26, 27]. Consequently, for the effective treatment of liver fibrosis, several nanoparticle (NP) systems have been developed [28, 29]. Using liposomes, polymers and special moieties, nanomedicines have mainly formulated for treating liver diseases [30]. However, majority of the NP systems for liver fibrosis are in the preclinical stage and the only kind of NPs in the clinical stage is liposomal nucleic acid carrier [31]. Chitosan-coated nanoliposomes were introduced for BBR hydrochloride oral delivery of [32]. In a recent article, polymer-lipid hybrid nanoparticles (PEG-lipid-PLGA NPs) loaded with BBR phospholipid complex were employed for increasing the oral BBR efficiency. BBR-soybean phosphatidylcholine complex (BBR-SPC) used to augment BBR liposolubility and improve the affinity with the biodegradable polymer to enhance the drug-loading capacity and sustained release [33].

Using soy phosphatidylcholine as emulsifiers BBR-loaded anhydrous reverse micelles (ARMs) or free BBR solutions were administered to

streptozocin (STZ)-induced diabetic mice. The oral bioavailability of BBR-loaded ARMs and the maximum blood concentration of BBR were enhanced leading to a prolonged efficacy [34]. Likewise, antidiabetic effect of BBR nanosuspension (Ber-NS) was assessed in STZ-induced diabetic mice. Chronic Ber-NS (50 mg/kg, p.o.) treatment reduced superior hypoglycemic, total cholesterol (TC) and body weight [35]. In a recent study, monodisperse microparticles loaded with the self-assembled BBR-phospholipid complex-based phytosomes to improve oral bioavailability of BBR and enhance its hypoglycemic efficiency [36]. cytoprotective efficacy of O-hexadecyl-dextran entrapped BBR chloride nanoparticles (BC-HDD NPs) were assessed in high glucose-stressed primary hepatocytes. BC-HDD NPs reduced ROS generation in the course of co-treatment, inhibited glutathione (GSH) depletion, reduced nitric oxide (NO) formation and markedly prevented decreased superoxide dismutase (SOD) activity in stressed cells. In addition, lipid peroxidation was stopped, the antioxidant capacity of the formulation was confirmed and the BC-HDD NPs at 20 fold lower concentrations was as effective as BBR [37].

The anti-fibrotic effect of chronic BBR (120 mg/kg/day, orally) was determined in BDL-induced liver fibrosis in a rat model [38]. Similarly, chronic BBR (10 mg/kg, i.p.) produced permeability normalization of hepatocytes plasma membranes and activity of microsomal flavin-containing monooxygenases in BDL rats [39].

Regarding the previous background, in the present study, hepatic fibrosis is induced by BDL in male rats and the possible hepatoprotective effect of nanoBBR is demonstrated compared to BBR and silymarin. Although hepatoprotective effects of BBR and silymarin were reported previously in liver fibrosis, there were no such reports on this kind of nano formulation of BBR for modification of cirrhosis in animal experiments.

MATERIALS AND METHODS

Chemicals

Berberine hydrochloride and silymarin were purchased from Sigma-Aldrich (USA). Berberine nanomicelle has been developed in Nanotechnology Research Center of Mashhad University of Medical Sciences, Mashhad, Iran and contained 5% berberine. Berberine nanomicelles have the average diameter of 2.7 nm.

Berberine (BBR) hydrochloride and silymarin (Sigma, St. Louis, MO, USA) were diluted freshly in saline before use.

Animals

Male rats (250-280 g) were obtained from the Laboratory Animal Centre of Tehran University of Medical Sciences, Tehran, Iran. The rats were let to acclimate a few days and fed with standard pellet diet and water ad libitum at 20-25°C under a 12 hour light/dark cycle. The food was removed one day before the experiment, but water was provided.

All animal handlings and experiment protocols processed (including drug treatment and sacrifice) was according with the guidelines of the Laboratory Animal Centre of the University of Tehran and in accordance with the international guidelines for laboratory animals.

Bile Duct Ligation Model

Bile duct ligation (BDL) was carried out to induce extrahepatic cholestasis-related liver fibrosis in rats [40]. Briefly, the rats were subjected to ligation of the common bile duct with 5-0 silk and sectioned between the ligatures under deep anesthesia using the cocktail with a mixture (1:1 v/v; 1 ml/kg body weight) of xylazine 2% (10 mg/kg) and ketamine 10% (50 mg/kg) intraperitoneally (i.p.) .

The abdominal midline was then closed with catgut. Moreover, the rats in a sham group had their bile duct exposed with neither ligation nor sectioning. All the rats were caged at 24°C with 12 hr: 12 hr light-dark cycle and were provided free access to food and water. All the operated rats except sham controls were randomized into distinct groups.

Animal treatments

Forty two rats were divided into 7 groups of six. Seven days following BDL, the rats in a BDL group received 50 mg/kg BBR nanomicelles dissolved in distilled saline by oral administration. The rats in BBR treatment groups received 50 and 100 mg/kg oral BBR dissolved in saline. Silymarin 100 mg/kg was also treated to one group. Moreover, a sham operated group was included in the study. Control groups were received saline as silymarin and BBR vehicle or nanomicelle as nanomicelle BBR vehicle. All the treatments lasted for three weeks every other day.

The serum biochemical markers analyses

Twenty-eight days following BDL, the blood (3 ml) was collected from the heart using sterile disposable syringes and the blood samples were centrifuged immediately at 8000 rpm (10 min. at 4 °C).

The serum samples (100 µL) were poured into new tubes and diluted with sodium chloride (400 µL 0.9%). To assess the liver function, serum levels of alanine aminotransferase (ALT), aspartate aminotransferase (AST) [Frankel-Reitman method (Ziest Chem. Diagnostics Kit, Iran) [22] and total bilirubin (TBIL) [Diazotized Sulfanilic Acid method (Ziest Chem. Diagnostics Kit, Iran)] were measured using the automatic biochemical analyzer according to the instructions [41]. Lactate dehydrogenase (LDH) was also determined [(Ziest Chem. Diagnostics Kit, Iran), DGKG ELISA/assay].

The hepatic tissue biochemical markers analyses

The liver samples were refrigerated in -70°C. The antioxidant status was assessed measuring superoxide dismutase (SOD) [42] and glutathione (GSH) [ELISA Kit (MBS265966MyBioSource), the USA] hepatic tissue levels. The total protein content was determined employing Biuret method with bovine serum albumine as standard [43].

Tissue levels of TNF-α were quantified using enzyme-linked immunosorbent assay [Rat TNF-α ELISA Kit (CSB-E11987r, CUSABIO and CUS Ab, the US)], according to the manufacturer's instructions.

Histological analysis

Histological evaluation was carried out to observe the morphological changes. The liver tissue was dissected out and fixed in 10% formalin solution, dehydrated in ethanol (50–100%), cleared in xylene and embedded in paraffin wax. thick sections (5–6 mm) were prepared and then stained with hematoxylin and eosin (H & E) for photomicroscopic observation.

An expert pathologist blinded to the study analyzed all the fragments using light microscopy. The fibrosis degree was measured based on the semi-quantitative scoring described [44]. Apoptotic cells were quantified based on morphological appearance (cell shrinkage with dense cytoplasm and peripheral condensation of nuclear chromatin). Ishak grade for fibrosis as (0-4), hepatitis (0-4) and necrosis (0-6) were counted in different aspects in each group.

Statistical analysis

The data were expressed as mean±standard deviation of means (SD) and statistical comparisons were conducted using one-way ANOVA (SPSS version 18) and LSD post-test. The values lower than 0.05 were considered significant changes.

RESULTS

Effects of berberine nanomicelles on serum biochemistry and hepatic antioxidative parameters

Fig 1 illustrates changes in serum AST and ALT levels in BDL rats (n=6) treated with silymarin (100 mg/kg, p.o.), BBR (50 and 100 mg/kg, p.o.) and BBR nanomicelle (50 mg/kg, p.o.). As can be understood, AST was significantly increased in BDL+saline group rats [F (5, 24)=42.294, P<0.001] compared to sham- operated group. Moreover, silymarin (100 mg/kg, p.o.), BBR (50 and 100 mg/kg, p.o.), BBR nanomicelle (50 mg/kg, p.o.) and nanomicelle groups had significantly higher AST levels compared to sham- operated group [F (5, 24)=42.294, P<0.001].

Silymarin (100 mg/kg, p.o.) and BBR (100 mg/kg, p.o.) and BBR nanomicelle (50 mg/kg, p.o.) markedly lowered AST level in BDL rats in comparison to BDL+saline group. [F (5, 24)=42.294, P<0.001], [F (5, 24)=42.294, P<0.01], [(5, 24)=42.294, P<0.001], respectively. In addition, compared to BBR nanomicelles (50 mg/kg, p.o.), sham- operated group had significantly lower AST level [F (5, 24)=42.294, P<0.001] while BDL+saline [F (5, 24)=42.294, P<0.001], BBR 50 mg/kg [F (5, 24)=42.294, P<0.001] and 100 mg/kg [F (5, 24)=42.294, P<0.01], and nanomicelle groups had markedly higher AST [F (5, 24)=42.294, P<0.001] (Fig 1a).

As can be observed, ALT was significantly increased in BDL+saline group rats [F (5, 24)=40.90, P<0.001] compared to sham-operated group. Moreover, silymarin (100 mg/kg, p.o.), BBR (50 and 100 mg/kg, p.o.), BBR nanomicelle (50 mg/kg, p.o.) and nanomicelle groups had significantly higher ALT levels compared to sham-operated group [F (5, 24)=40.90, P<0.001]. Silymarin (100 mg/kg, p.o.) and BBR (100 mg/kg, p.o.) markedly lowered ALT level [F (5, 24)=40.90, P<0.001], [F (5, 24)=40.90, P<0.01], respectively in BDL rats in comparison to BDL+saline group. Notably, BBR nanomicelle (50 mg/kg, p.o.) profoundly reduced ALT level [(5, 24)=40.90, P<0.001] in BDL group compared to BDL+saline group. In addition, compared to BBR nanomicelles (50 mg/kg, p.o.),

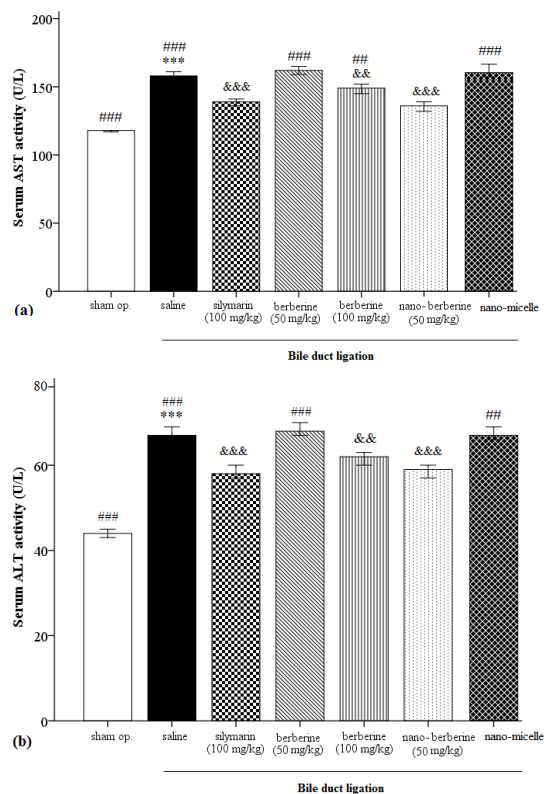


Fig 1. Changes in AST (Fig 1a) and ALT (Fig. 1b) serum levels in BDL rats treated with silymarin (100 mg/kg, p.o.), BBR (50 and 100 mg/kg, p.o.) and BBR nanomicelle (50 mg/kg, p.o.). ***P<0.001 significantly different from sham operated group. &&P<0.01 significantly different from BDL + saline group. ## P<0.01 and ### P<0.001 significantly different from BD +nanomicelle group

sham- operated group had significantly lower ALT level [F (5, 24)=40.90, P<0.001] while BDL+saline, BBR 50 mg/kg [F (5, 24)=40.90, P<0.001] and nanomicelle groups [F (5, 24)=40.90, P<0.01] had markedly higher ALT levels (Fig 1b). Fig 2 illustrates changes in serum TBIL and LDH levels in BDL rats (n=6) treated with silymarin (100 mg/kg, p.o.), BBR (50 and 100 mg/kg, p.o.) and BBR nanomicelle (50 mg/kg, p.o.). As can be understood, TBIL was significantly increased in BDL+saline group rats [F (5, 30)=13.453, P<0.001] compared to sham-operated group. Moreover, silymarin (100 mg/kg, p.o.) [F (5, 30)=13.453, P<0.01], BBR (50 and 100 mg/kg, p.o.) [F (5, 30)=13.453, P<0.001], BBR nanomicelle (50 mg/kg, p.o.) [F (5, 30)=13.453, P<0.01] and nanomicelle [F (5, 30)=13.453, P<0.001] groups had significantly higher TBIL levels. Notably, BBR nanomicelle (50 mg/kg, p.o.) profoundly reduced TBIL level [(5, 30)=13.453,

P<0.05] in BDL group compared to BDL+saline group. In addition, compared to BBR nanomicelles (50 mg/kg, p.o.), sham- operated group had significantly lower TBIL level [F (5, 30)=13.453, P<0.01] while nanomicelle group had markedly higher TBIL level [F (5, 30)=13.453, P<0.01] (Fig 2a).

As can be understood, LDH was significantly increased in BDL+ saline group rats [F (5, 24)=3.76, P<0.05] compared to sham-operated group. Moreover, BBR (50 mg/kg, p.o.) and nanomicelle groups still had markedly higher LDH levels [F (5, 24)=3.76, P<0.05] compared to sham- operated group. Notably, Silymarin (100 mg/kg, p.o.) and BBR nanomicelle (50 mg/kg, p.o.) profoundly reduced LDH level [(5, 24)=3.76, P<0.05] in BDL group compared to BDL + saline group. In addition, compared to BBR nanomicelles (50 mg/kg, p.o.), BDL+ saline, BBR 50 mg/kg and nanomicelle groups had markedly higher LDH levels [F (5, 24)=3.76, P<0.05] (Fig 2b).

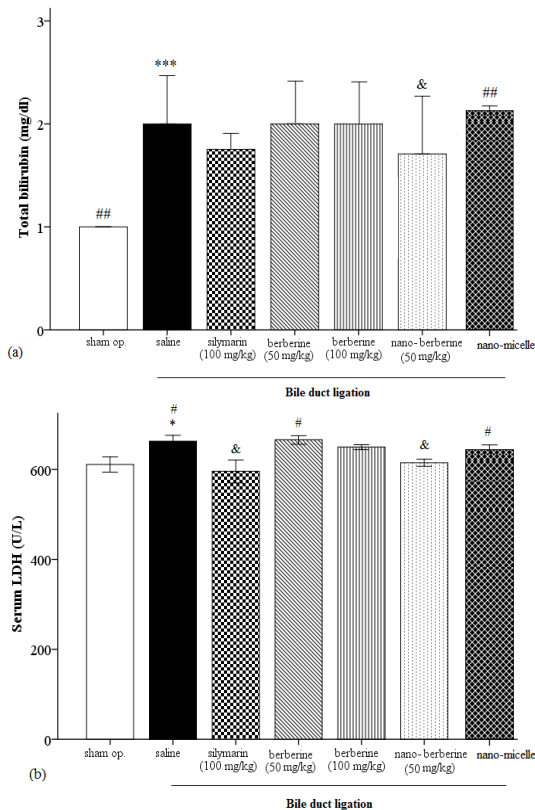


Fig 2. Changes in serum total bilirubin and LDH levels in BDL rats (n=6) treated with silymarin (100 mg/kg, p.o.), BBR (50 and 100 mg/kg, p.o.) and BBR nanomicelle (50 mg/kg, p.o.). ***P<0.01 significantly different from sham operated group. & P<0.05 significantly different from BDL + saline group

Effects of berberine nanomicelles on tissue biochemistry and hepatic antioxidative parameters

Fig 3 illustrates changes in hepatic tissue GSH and SOD levels in BDL rats (n=6) treated with silymarin (100 mg/kg, p.o.), BBR (50 and 100 mg/kg, p.o.) and BBR nanomicelles (50 mg/kg, p.o.). As can be understood, GSH was significantly decreased in BDL+saline group rats [F (5, 24)=40.69, P<0.001] compared to sham- operated group.

Moreover, BBR (50 and 100 mg/kg, p.o.) and nanomicelle groups had significantly lower GSH levels compared to sham-operated group. Silymarin (100 mg/kg, p.o.) and BBR nanomicelle (50 mg/kg, p.o.) markedly enhanced GSH level [F (5, 24)=40.69, P<0.001] in BDL rats in comparison to BDL+ saline group. In addition, compared to BBR nanomicelles (50 mg/kg, p.o.), sham-operated group had significantly higher GSH level [F (5, 24)=40.69, P<0.01] while BDL+saline, BBR 50 mg/kg and BBR 100 mg/kg and nanomicelle groups had markedly lower GSH levels [F (5, 24)=40.69, P<0.001] (Fig 3a).

As can be observed, SOD was significantly decreased in BDL+saline group rats [F (5, 24)=18.60, P<0.001] compared to sham- operated group. In addition, silymarin 100 mg/kg and BBR 50 mg/kg had significantly lower SOD levels compared to sham-operated group [F (5, 24)=18.60, P<0.05] and [F (5, 24)=18.60, P<0.001], respectively. Notably, silymarin (100 mg/kg, p.o.), BBR (100 mg/kg, p.o.) and BBR nanomicelle (50 mg/kg, p.o.) markedly enhanced SOD level [F (5, 24)=18.60, P<0.01], [(5, 24)=18.60, P<0.001], respectively, in BDL rats in comparison to BDL+saline group. In addition, compared to BBR nanomicelles (50 mg/kg, p.o.), BDL+ saline, BBR 50 mg/kg and nanomicelle groups had markedly lower SOD levels [F (5, 24)=18.60, P<0.001] (Fig 3b).

Fig 3. Changes in GSH and SOD tissue levels in BDL rats (n=6) treated with silymarin (100 mg/kg, p.o.), BBR (50 and 100 mg/kg, p.o.), BBR nanomicelle (50 mg/kg, p.o.) and nanomicelle. ***P<0.001 significantly different from sham operated group. &&P<0.01 and &&& P<0.001 significantly different from BDL+saline group. ## P<0.01 and ### P<0.001 significantly different from BDL + BBR nanomicelle group.

Fig 4 shows changes in hepatic tissue total protein levels in BDL rats (n=6) treated with

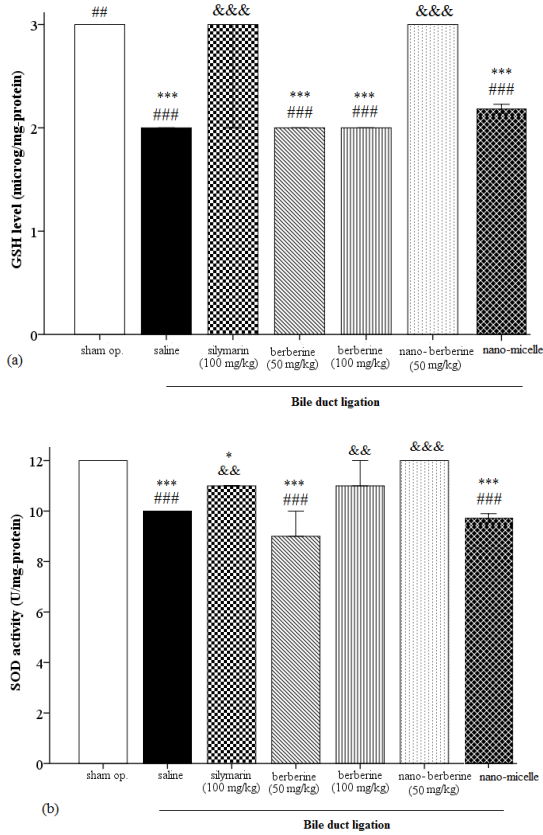


Fig 3. Changes in GSH and SOD tissue levels in BDL rats (n=6) treated with silymarin (100 mg/kg, p.o.), BBR (50 and 100 mg/kg, p.o.), BBR nanomicelle (50 mg/kg, p.o.) and nanomicelle. ***P<0.001 significantly different from sham operated group. &&P<0.01 and &&&P<0.001 significantly different from BDL + saline group. ##P<0.01 and ###P<0.001 significantly different from BDL + BBR nanomicelle group

silymarin (100 mg/kg, p.o.), BBR (50 and 100 mg/kg, p.o.) and BBR nanomicelle (50 mg/kg, p.o.). As can be understood, total protein was significantly reduced in BDL rats [F (5, 24)=6.072, P<0.001] compared to sham-operated group. Moreover, silymarin (100 mg/kg, p.o.) [F (5, 24)=6.072, P<0.01], BBR (50 and 100 mg/kg, p.o.) [F (5, 24)=6.072, P<0.001], BBR nanomicelle (50 mg/kg, p.o.) [F (5, 24)=6.072, P<0.01] and nanomicelle [F (5, 24)=6.072, P<0.001] groups had significantly lower protein levels compared to sham-operated group. In addition, compared to BBR nanomicelles (50 mg/kg, p.o.), sham group had markedly higher total protein levels [F (5, 24)=6.072, P<0.01].

Fig 5 shows changes in hepatic tissue TNF- α levels in BDL rats (n=6) treated with silymarin (100 mg/kg, p.o.), BBR (50 and 100 mg/kg, p.o.) and BBR nanomicelle (50 mg/kg, p.o.). As can be

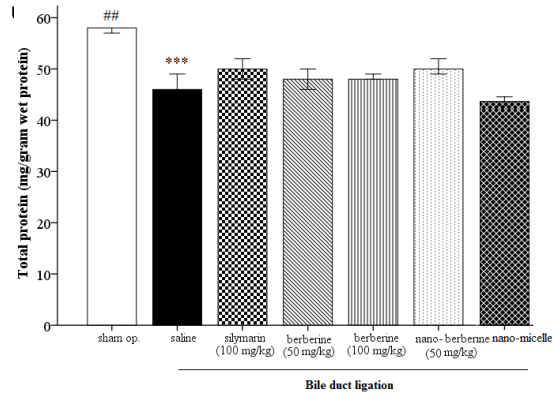


Fig 4. Changes in hepatic tissue total protein levels in BDL rats (n=6) treated with silymarin (100 mg/kg, p.o.), BBR (50 and 100 mg/kg, p.o.) and BBR nanomicelle (50 mg/kg, p.o.). ***P<0.001 significantly different from sham operated group

BDL rats [F (5, 30)=5.258, P<0.01] compared to sham-operated group.

Moreover, silymarin 100 mg/kg, BBR 50 and 100 mg/kg and nanomicelle groups still had significantly higher TNF- α levels compared to sham-operated group [F (5, 30)=5.258, P<0.01]. Notably, BBR nanomicelle (50 mg/kg, p.o.) lowered TNF- α level in BDL rats in a significant manner [F (5, 30)=5.285, P<0.05] compared to BDL+saline group.

In addition, compared to BBR nanomicelles (50 mg/kg, p.o.), sham group had markedly lower total protein levels [F (5, 30)=5.285, P<0.01] while nanomicelle group had higher level [F (5, 30)=5.285, P<0.01].

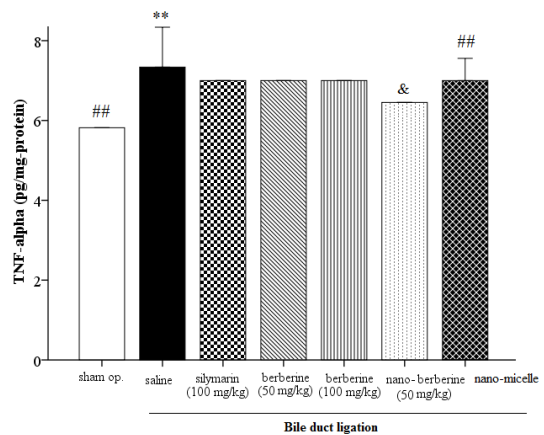


Fig 5. Changes in hepatic tissue TNF- α levels in BDL rats (n=6) treated with silymarin (100 mg/kg, p.o.), BBR (50 and 100 mg/kg, p.o.) and BBR nanomicelle (50 mg/kg, p.o.). **P<0.01 significantly different from sham operated group. ##P<0.01 significantly different from BDL + nanomicelle group

Table 1. Semi-quantitative scores of hepatic fibrosis (Ishak's score) 28 days after (BDL)

Score/ groups	Ishak grade for fibrosis						
	Nano BBR	BBR 50 mg/kg	BBR 100 mg/kg	Silymarin 100 mg	micelle	BDL	sham
No fibrosis (0)	x		x				x
Fibrous portal expansion (1)		x		x			
Few bridges or septa(2)							
Numerous bridges or septa (3)					x		
Cirrhosis (4)						x	
	Ishak grade for hepatitis						
None (0)	x						x
Mild (focal, few portal areas):(1)			x				
Mild/moderate (focal, most portal areas (2)		x		x		x	
Moderate (continuous around < 50% of tracts or septa):(3)					x		
Severe (continuous around > 50% of tracts or septa (4)							
	Ishak grade for necrosis						
None (0)							x
Focal confluent necrosis (1)	x		x	x			
Zone 3 necrosis in some areas (2)					x		
Zone 3 necrosis in most areas (3)		x					
Zone 3 necrosis + occasional portal-central bridging (4)						x	
Zone 3 necrosis + multiple portal-central bridging (5)							
Panacinar or multiacinar necrosis (6)							

Morphological results (Pathological outcomes)

Fig 6 represents microphotographs of the liver sections from BDL and sham-operated rats. Sham-operated rats with normal liver architecture and the lack of fibrosis (Score 0); BDL rats at 4 weeks showing fibrous expansion of portal areas with marked portal-to-portal as well as portal-to-central bridging (score 4). There were dense connective tissue bands that have formed throughout the sinusoids and portal area. Proliferation of bile ducts were seen (arrows), there was hepatic congestion (large arrow) On the other hand, silymarin (100 mg/kg, p.o.) group showed mild fibrosis of periportal areal and hepatic necrosis (small arrows) (score 2) and showed hepatocyte necrosis (small arrow) and focal fibrosis; deposition of fine collagen fibers in the sinusoids of the pericentral lobular region, (large arrow). In addition, BBR (100 mg/kg, p.o.) showed multifocal necrotic changes in hepatocytes around central vein (score 3) and showed hepatocyte necrosis in portal area and multifocal necrotic changes in hepatocytes around central vein. Moreover, nanoBBR (50 mg/kg,

p.o.) rats had virtually normal liver architecture and the absence of fibrosis (score 1) and showed hepatocyte apoptosis; (small and rounded cells with hypereosinophilic cytoplasm and small, fragmented nuclei. Images mag: 400x.

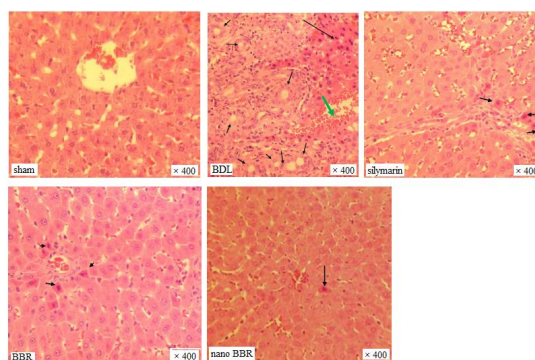


Fig 6. Representative microphotographs of the liver sections from BDL and sham-operated rats

Table 1 illustrated semi-quantitative scores of hepatic fibrosis (Ishak's score) 28 days after (BDL). Because no difference in the many

variables studied in the sham group 28 days after sham operation was observed, results from all the sham-operated groups were gathered for presentation. Hepatic fibrosis deteriorated over the time after BDL. Regarding the Ishak's score, the following score values for each BDL group were obtained: sham operated rats scored 0 (normal hepatic architecture), 4-wk rats scored 4 (fibrous expansion of portal tracts with marked portal to-portal and portal-to-central bridging).

DISCUSSION

In the present study, hepatic fibrosis was induced by BDL in male rats and the possible hepatoprotective effect of nanoBBR, compared to BBR and silymarin, was demonstrated. The results illustrated that BDL completely blocked bile flow as evidenced by elevation of serum TBIL, AST, ALT, LDH and TNF- α , key biomarkers of hepatocyte injury. In addition, BDL impaired antioxidant defense as evidenced by significant reduction in antioxidant enzymes GSH, SOD and total protein contents. On the other hand, silymarin, BBR (100 mg/kg) and BBR nanomicelles markedly decreased serum levels of AST and ALT while only silymarin and BBR nanomicelles could lower LDH serum levels. silymarin and BBR nanomicelles enhanced GSH level. Furthermore, BBR nanomicelles (50 mg/kg, p.o.), silymarin (100 mg/kg, p.o.) and BBR (100 mg/kg, p.o.) groups showed a considerable increase in SOD levels. Moreover, only BBR nanomicelles significantly lowered the pro-inflammatory cytokine TNF- α level. Consistently, histological changes consist of cell necrosis, fatty metamorphosis in adjacent hepatocytes, ballooning degeneration, infiltration of lymphocytes and Kupffer cells, pseudolobuli and bridging formation have been observed in the liver tissue of BDL group, and these histopathologic changes were considerably diminished by nano-berberine treatment. In fact, effect of nanoBBR compared to BBR and silymarin groups was noticeable, although silymarin [45] and BBR [21, 46] have widely recognized as potent hepatoprotective agents, and nanoBBR showed its effect in significantly lower dose.

In BDL rats, chronic silymarin (300 mg/kg) had hepatoprotective effect [47]. Notably, formulation of silymarin as nanoparticles, silymarin-loaded Eudragit ([®]) RS100 nanoparticles (SMnps) (125 mg/kg, p.o.), improved its ability to eliminate cholestasis-induced liver fibrosis in rats by

restoring hepatic regenerative capabilities [48].

The mitochondrial functions were studied in BDL rats and suggested that biochemical and molecular alterations are related to oxidative stress in the liver [13]. Further, the rise in serum levels of ALP, AST and ALT has been ascribed to structural integrity damage of the liver [49], because these are cytoplasmic in location and are released into circulation after cellular damage [50]. The TNF- α expression also elevates in acute liver diseases, as well as in hepatotoxic chemicals exposure [51, 52]. Moreover, GSH as a key antioxidant is an important part of intracellular protective mechanisms against numerous noxious stimuli, including oxidative stress. Notably, these changes in our experiment were in line with these studies. In line with previous reports, our results also demonstrated that depletion of tissue GSH, as observed in BDL-induced hepatic injury, is one of the major factors that permit lipid peroxidation and subsequent tissue damage. Similarly, in our study plasma antioxidant capacity was also decreased. Because administration of nanoBBR prevented hepatic GSH depletion, it appears that its protective effect involves the maintenance of antioxidant capacity by protecting the hepatic tissue against oxidative stress.

In agreement with our study, the anti-fibrotic effect of chronic BBR (120 mg/kg/day, orally) was determined in a rat model of BDL-induced liver fibrosis. BBR potently inhibited hepatic fibrosis. Significant elevations of serum ALT and AST were observed in BDL rats and BBR treatment remarkably reduced their levels [38]. Chronic BBR administration (10 mg/kg, i.p.) resulted in a partial normalization of permeability of plasma membranes hepatocytes in BDL rats. Membrane-stabilizing effect of BBR was probably related to inhibition of pro-oxidant status of the liver cells [39].

In a clinical study, chronic BBR (0.5 g, p.o.) and silymarin (70 mg, p.o.) reduced the blood lipids (ALT and AST levels) in hyperlipidemic patients with either chronic hepatitis or liver cirrhosis [53].

The hepatoprotective effects of BBR (80, 120 and 160 mg/kg, p.o.) on carbon tetrachloride (CCl₄)-induced liver injury was shown in rat. Serum ALT and AST activities markedly decreased in pre- and post-treatment groups in a dose-dependent manner. BBR increased SOD activity in the liver as well. Histological assessments showed decrease in the liver damage in BBR-treated groups [54]. Consistent with our experiment, the

decreased hepatic activity of SOD and increased lipid peroxidation were profoundly prevented by BBR (10 mg/mg) administration in CCl₄-intoxicated mice. The increased serum levels of ALT, AST, and ALP were significantly prevented by BBR treatment in a concentration-dependent manner. Moreover, histopathological changes were diminished and the expression of TNF- α , cyclooxygenase-2 (COX-2), and inducible nitric oxide synthase (iNOS) was markedly reduced. BBR prevent acute hepatotoxicity attenuating oxidative and nitrosative stress as well as the inflammatory responses in the liver [55]. BBR decreased ALT, AST, and ALP levels the in serum, enhanced SOD and reduced malondialdehyde (MDA) content of the liver tissue in CCl₄-induced liver fibrosis in mice [56].

Apart from the kind of inflammatory stimulus, BBR effectively suppresses proinflammatory cytokines expression, including TNF- α , subsequently, inhibiting downstream mediators of inflammation, like iNOS and COX-2 [57, 58]. Moreover, BBR ameliorated fatty acid-induced oxidative stress in human hepatoma cells. It also had the capacity to reduce lipid accumulation in the livers of high fat-diet fed mice [59].

Chronic pretreatment with BBR (0.5 and 5 mg/kg, i.p.) before a single dose of tert-butyl hydroperoxide (t-BHP) (0.1 mmol/kg) significantly lowered the serum levels of ALT and AST and reduced oxidative stress in the liver. BBR (0.01–1.0 mM) treatment markedly decreased the leakage of lactate dehydrogenase (LDH) and ALT, and the formation of MDA. BBR also attenuated t-BHP- induced depletion of GSH. The histopathological evaluation of the livers clarified the occurrence of the liver lesions, for example, hepatocyte swelling, leukocyte infiltrations, and necrosis was lowered [20].

Though effects of nanoBBR formulations have rarely reported on liver fibrosis, virtually consistent with our investigation, the effects of BBR-loaded solid lipid nanoparticles (BBR-SLNs) on lipid metabolism in the liver were investigated. The results showed that BBR-SLNs (100 mg/kg, p.o.) inhibited the increase in the body weight and decrease in the liver weight, in parallel with the reduction in serum ALT and the liver triglyceride levels in mice. The maximum concentration of drug in the liver was 20-fold higher than that in the blood. BBR-SLNs significantly lowered fat accumulation and lipid droplet sizes in the liver [60].

In our study, impairments in hepatic functions

and antioxidant capacity owing to biliary obstruction were substantially improved following nanoBBR treatments, while the serum level of the pro-inflammatory cytokine TNF- α was reduced. Increased TNF- α level which tended to decrease with nanoBBR treatment also supports the concept that nanoBBR ameliorates oxidative liver injury caused by BDL partly through its antioxidant capacity.

CONCLUSION

These findings suggest that nanoBBR may be protective in biliary obstruction-induced oxidative injury and fibrosis by inhibition and subsequent activation of inflammatory mediators, which induce lipid peroxidation. Moreover, the protective capacity of nanoBBR may probably be attributed to its role as a free radical scavenger and the inhibition of inflammatory response in the liver. BBR nano micelle might be a promising factor for treating the liver fibrosis. Nevertheless, its value as an antifibrotic drug in patients with liver disease demands further complementary studies.

ACKNOWLEDGMENTS

We would like to thanks Department of Pharmacology, School of Medicine, Tehran University of Medical Sciences, Tehran, Iran for its collaboration and support.

REFERENCES

1. Lee KS, Buck M, Houghlum K, Chojkier M. Activation of hepatic stellate cells by TGF alpha and collagen type I is mediated by oxidative stress through c-myc expression. *J Clin Invest.* 1995; 96: 2461–2468.
2. Serviddio G, Pereda J, Pallardó FV, Carretero J, Borrás C, Cutrin J, Vendemiale G, Poli G, Viña J, Sastre J. Ursodeoxycholic acid protects against secondary biliary cirrhosis in rats by preventing mitochondrial oxidative stress. *Hepatology.* 2004; 39: 711–720.
3. Antoine M., Tag CG, Wirz W, Borkham-Kamphorst E, Sawitzka I, Gressner AM, Kiefer P. Upregulation of pleiotrophin expression in rat hepatic stellate cells by PDGF and hypoxia: implications for its role in experimental biliary liver fibrogenesis. *Biochem Biophys Res Commun* 2005; 337: 1153-1164.
4. Sztrymf B, JM Libert, Mougeot C, Lebrec D, Mazmanian M, Humbert M, Herve P. Cirrhotic rats with bacterial translocation have higher incidence and severity of hepatopulmonary syndrome. *J Gastroenterol Hepatol.* 2005; 20: 1538-1544.
5. Liu TZ, Lee KT, Chern CL, Cheng JT, Stern A, Tsai LY. Free radical-triggered hepatic injury of experimental obstructive jaundice of rats involves overproduction of proinflammatory cytokines and enhanced activation of nuclear factor kappaB. *Ann Clin Lab Sci.* 2001; 31: 383–390.

6. Aziz TA, Aziz MA, Fouad HH, Rashed LA, Salama H, Abd-Alla S, Wehab MA, Ahmed T. Interferon-alpha gene therapy prevents aflatoxin and carbon tetrachloride promoted hepatic carcinogenesis in rats. *Int J Mol Med.* 2005; 15: 21-26.
7. Hines JE, Johnson SJ, Burt AD. In vivo responses of macrophages and perisinusoidal cells to cholestatic liver injury. *Am J Pathol.* 1993; 142: 511-518.
8. Poli G, Parola M. Oxidative damage and fibrogenesis. *Free Radic Biol Med.* 1997; 22: 287-305.
9. Dahm LJ, Hewett JA, Roth RA. Bile and bile salts potentiate superoxide anion release from activated rat peritoneal neutrophils. *Toxicol Appl Pharmacol.* 1988; 95: 82-92.
10. Singh S, Shackleton G, Ah-Sing E, Chakraborty J, Bailey ME. Antioxidant defenses in the bile duct-ligated rat. *Gastroenterology.* 1992; 103: 1625-1629.
11. Poli G. Pathogenesis of liver fibrosis: role of oxidative stress. *Mol Aspects Med.* 2000; 21: 49-98.
12. Parola M, Robino G. Oxidative stress-related molecules and liver fibrosis. *J Hepatol.* 2001; 35: 297-306.
13. YT Huang, YC Hsu, CJ Chen, CT Liu, YH Wei. Oxidative stress-related changes in the livers of bile-duct-ligated rats. *J Biomed Sci.* 2003; 10: 170-178.
14. Wang A. *Essentials of Materia Medica.* Chongqing: Chongqing University Press, 1996: 104.
15. Kulkarni S, Dhir A. Berberine: a plant alkaloid with therapeutic potential for central nervous system disorders. *Phytother Res.* 2010; 24: 317-324.
16. Saha P, Bhattacharjee S, Sarkar A, Manna A, Majumder S, Chatterjee M. Berberine chloride mediates its anti-leishmanial activity via differential regulation of the mitogen activated protein kinase pathway in macrophages. *PLoS ONE.* 2011; 6: 18467.
17. Zheng HY, Xu WR. Research progression of pharmacologic actions of Umbellatine. *Chin Tradit Herbal Drugs.* 2004; 35: 708-711.
18. Domitrović R, Jakovac H, Marchesi VV, and Blažeković B. Resolution of liver fibrosis by isoquinoline alkaloid berberine in CCl4-intoxicated mice is mediated by suppression of oxidative stress and upregulation of MMP-2 expression. *J Med Food.* 2013; 16: 518-528.
19. Sheng M, Zhou Y, Yu W, Weng Y, Xu R, Du H. Protective effect of berberine pretreatment in hepatic ischemia/reperfusion injury of rat. *Transplant Proc.* 2015; 47: 275-82.
20. Hwang JM, Wang CJ, Chou FP, Tseng TH, Hsieh YS, Lin WL, Chu CY. Inhibitory effect of berberine on tert-butyl hydroperoxide-induced oxidative damage in rat liver. *Arch Toxicol.* 2002; 76: 664-670.
21. Zhang BJ, Xu D, Guo Y, Ping J, Chen LB, Wang H. Protection by and anti-oxidant mechanism of berberine against rat liver fibrosis induced by multiple hepatotoxic factors. *Clin Exp Pharmacol Physiol.* 2008; 35: 303-309.
22. Janbaz KH, Gilani AH. Studies on preventive and curative effects of berberine on chemical-induced hepatotoxicity in rodents. *Fitoterapia.* 2000; 71: 25-33.
23. Tan X, Ma J, Feng R, Ma C, Chen W, Sun Y. Tissue distribution of berberine and its metabolites after oral administration in rats. *PLoS ONE.* 2013; 8: 77969.
24. Liu Y, Hao H, Xie H, Lai L, Wang Q, Liu C, Wang G. Extensive intestinal first pass elimination and predominant hepatic distribution of berberine explain its low plasma levels in rats. *Drug Metab Dispos.* 2010; 38: 1779-1784.
25. Zhang P, Qiang X, Zhang M, Ma D, Zhao Z, Zhou C, Liu X, Li R, Chen H, Zhang Y. Demethyleneberberine, a natural mitochondria-targeted antioxidant, inhibits mitochondrial dysfunction, oxidative stress, and steatosis in alcoholic liver disease mouse model. *J Pharmacol Exp Ther.* 2015; 352 : 139-147.
26. Pellicoro A, Ramachandran P, Iredale JP, Fallowfield JA. Liver fibrosis and repair: immune regulation of wound healing in a solid organ. *Nat Rev Immunol.* 2014; 14: 181-194.
27. Czaja AJ. Hepatic inflammation and progressive liver fibrosis in chronic liver disease. *World J Gastroenterol.* 2014; 20: 2515-2532.
28. Chithrani DB. Nanoparticles for improved therapeutics and imaging in cancer therapy. *Recent Pat Nanotechnol.* 2010; 4: 171-180.
29. Henweeer C, Gendy SE, Peñate-Medina O. Liposomes and inorganic nanoparticles for drug delivery and cancer imaging. *Ther Deliv.* 2012; 3: 645-656.
30. Torchilin VP. Multifunctional, stimuli-sensitive nanoparticulate systems for drug delivery. *Nat Rev Drug Discov.* 2014; 13: 813-827.
31. Surendran SP, Thomas RG, Moon MJ, and YY Jeong. Nanoparticles for the treatment of liver fibrosis. *Int J Nanomedicine.* 2017; 12: 6997-7006.
32. Nguyen TX, Huang L, Liu L, Elamin Abdalla AM, Gauthier M and Yang G. Chitosan-coated nano-liposomes for the oral delivery of berberine hydrochloride. *J Mater Chem B.* 2014; 2: 7149-7159.
33. Yu F, Ao M, Zheng X, Li N, Xia J, Li Y, Li D, Hou Z, Qi Z, Chen XD. PEG-lipid-PLGA hybrid nanoparticles loaded with berberine-phospholipid complex to facilitate the oral delivery efficiency. *Drug Deliv.* 2017; 24: 825-833.
34. Wang T, Wang N, Song H, Xi X, Wang J, Hao A, Li T. Preparation of an anhydrous reverse micelle delivery system to enhance oral bioavailability and anti-diabetic efficacy of berberine. *Eur J Pharm Sci.* 2011; 44: 127-135.
35. Wang Z, Wu J, Zhou Q, Wang Y, Chen T. Berberine nanosuspension enhances hypoglycemic efficacy on streptozotocin induced diabetic C57BL/6 mice. *Evid Based Complement Alternat Med.* 2015; 2015: 239749.
36. Yu F, Li Y, Chen Q, He Y, Wang H, Yang L, Guo S, Meng Z, Cui J, Xue M, Chen XD. Monodisperse microparticles loaded with the self-assembled berberine-phospholipid complex-based phytosomes for improving oral bioavailability and enhancing hypoglycemic efficiency. *Eur J Pharm Biopharm.* 2016; 103: 136-148.
37. Kapoor R, Singh S, Tripathi M, Bhatnagar P, Kakkar P, Gupta KC. O-hexadecyl-dextran entrapped berberine nanoparticles abrogate high glucose stress induced apoptosis in primary rat hepatocytes. *PLoS One.* 2014; 9: 89124.
38. Wang N, Xu Q, Tan HY, Hong M, Li S, Yuen MF, Feng Y. Berberine inhibition of fibrogenesis in a rat model of liver fibrosis and in hepatic stellate cells. *Evid Based Complement Alternat Med.* 2016; 2016: 8762345.
39. Zverinskiĭ IV, Meĭnichenko NG, Poplavskii VA, Sut'ko IP, Telegin PG, Shliakhtun AG. The effect of berberine administration of evaluation of the functional state of rat liver after ligation of common bile duct. *Biomed Khim.* 2013; 59: 90-96.
40. Soyulu AR, Aydogdu N, Basaran UN, Altaner S, Tarcin O, Gedik N, Umit H, Tezel A, Dokmeci G, Baloglu H, Ture M. Antioxidants vitamin E and C attenuate hepatic fibrosis in biliary-obstructed rats. *World J Gastroenterol.* 2006; 12:

- 6835-6841.
41. Jin H, Baode S, He X, Ling D, Hailong Y. Daily administration times of canhuang tablet based on a pharmacodynamic/pharmacokinetic model in jaundiced rats. *J Tradit Chin Med.* 2015; 35: 84-89.
 42. Marklund S, Marklund G. Involvement of the superoxide anion radical in the autoxidation of pyrogallol and a convenient assay for superoxide dismutase. *Eur J Biochem.* 1974; 47: 469-474.
 43. Annino JS, Gese RW. *Clinical Chemistry Principles and Procedures*, 4 edition. Little, Brown and Company, Boston, 1976.
 44. Ishak K, Baptista A, Bianchi L, Callea F, De Groote J, Gudat F, Denk H, Desmet V, Korb G, MacSween RN. Histological grading and staging of chronic hepatitis. *J Hepatol.* 1995; 22: 696-699.
 45. Hellerbrand C, Schattenberg JM, Peterburs P, Lechner A, Brignoli R. The potential of silymarin for the treatment of hepatic disorders. *Clin Phytoscience.* 2016; 2: 7.
 46. Sun X, Zhang X, Hu H, Lu Y, Chen J, Yasuda K, Wang H. Berberine Inhibits Hepatic Stellate Cell Proliferation and Prevents Experimental Liver Fibrosis. *Biol Pharm Bull.* 2009; 32: 1533-1537.
 47. Onalan AK, Tuncal S, Kilicoglu S, Celepli S, Durak E, Kilicoglu B, Devrim E, Barlas AM, Kismet K. Effect of silymarin on oxidative stress and liver histopathology in experimental obstructive jaundice model. *Acta Cir Bras.* 2016; 31: 801-806.
 48. Younis N, Shaheen MA, Abdallah MH. Silymarin-loaded Eudragit(®) RS100 nanoparticles improved the ability of silymarin to resolve hepatic fibrosis in bile duct ligated rats. *Biomed Pharmacother.* 2016; 81: 93-103.
 49. MB Chenoweth, CL Hake. The smaller halogenated aliphatic hydrocarbons. *Ann Rev Pharmacol.* 1962; 2: 363.
 50. Sallie R, Tredger JM, William R. *Drugs and the liver. Part I., Testing liver function*, *Biopharm Drug Disp.* 1991; 12: 251-259.
 51. Luster MI, Simeonova PP, Gallucci R, Matheson J. Tumor necrosis factor- α and toxicology. *Crit Rev Toxicol.* 1999; 29: 491-511.
 52. Simeonova PP, Gallucci RM, Hulderman T, Wilson R, Kommineni C, Rao M, Luster MI. The role of tumor necrosis factor- α in liver toxicity, inflammation, and fibrosis induced by carbon tetrachloride. *Toxicol Appl Pharmacol.* 2001; 177: 112-120.
 53. Zhao W, Xue R, Zhou ZX, Kong WJ, Jiang JD. Reduction of blood lipid by berberine in hyperlipidemic patients with chronic hepatitis or liver cirrhosis. *Biomed Pharmacother.* 2008; 62: 730-731.
 54. Feng Y, Siu KY, Ye X, Wang N, Yuen MF, Leung CH, Tong Y, Kobayashi S. Hepatoprotective effects of berberine on carbon tetrachloride-induced acute hepatotoxicity in rats. *Chin Med.* 2010; 5: 33.
 55. Domitrovic R, Jakovac H, Blagojevic G. Hepatoprotective activity of berberine is mediated by inhibition of TNF- α , COX-2, and iNOS expression in CCl₄-intoxicated mice. *Toxicology.* 2011; 280: 33-43.
 56. Li J, Pan Y, Kan M, Xiao X, Wang Y, Guan F, Zhang X, Chen L. Hepatoprotective effects of berberine on liver fibrosis via activation of AMP-activated protein kinase. *Life Sci.* 2014; 98: 24-30.
 57. Hsiang CY, Wu SL, Cheng SE, Ho TY. Acetaldehyde-induced interleukin-1 β and tumor necrosis factor- α production is inhibited by berberine through nuclear factor- κ B signaling pathway in HepG2 cells. *J Biomed Sci.* 2005; 12: 791-801.
 58. Jeong HW, Hsu KC, Lee JW, Ham M, Huh JY, Shin HJ, Kim WS, Kim JB. Berberine suppresses proinflammatory responses through AMPK activation in macrophages. *Am J Physiol Endocrinol Metab.* 2009; 296: 955-964.
 59. Sun Y, Yuan X, Zhang F, Han Y, Chang X, Xu X, Li Y, Gao X. Berberine ameliorates fatty acid-induced oxidative stress in human hepatoma cells. *Sci Rep.* 2017; 7: 11340.
 60. M. Xue, L. Zhang, M.X Yang., W. Zhang, X.M. Li, Z.M. Ou, Z.P. Li, S.H. Liu, X.J. Li, S.Y. Yang. Berberine-loaded solid lipid nanoparticles are concentrated in the liver and ameliorate hepatosteatosis in db/db mice. *Int J Nanomedicine.* 2015; 10: 5049-5057.